

# Ultrasound-Guided Hip Arthrocentesis

*Highland General Hospital  
Division of Emergency Ultrasound*

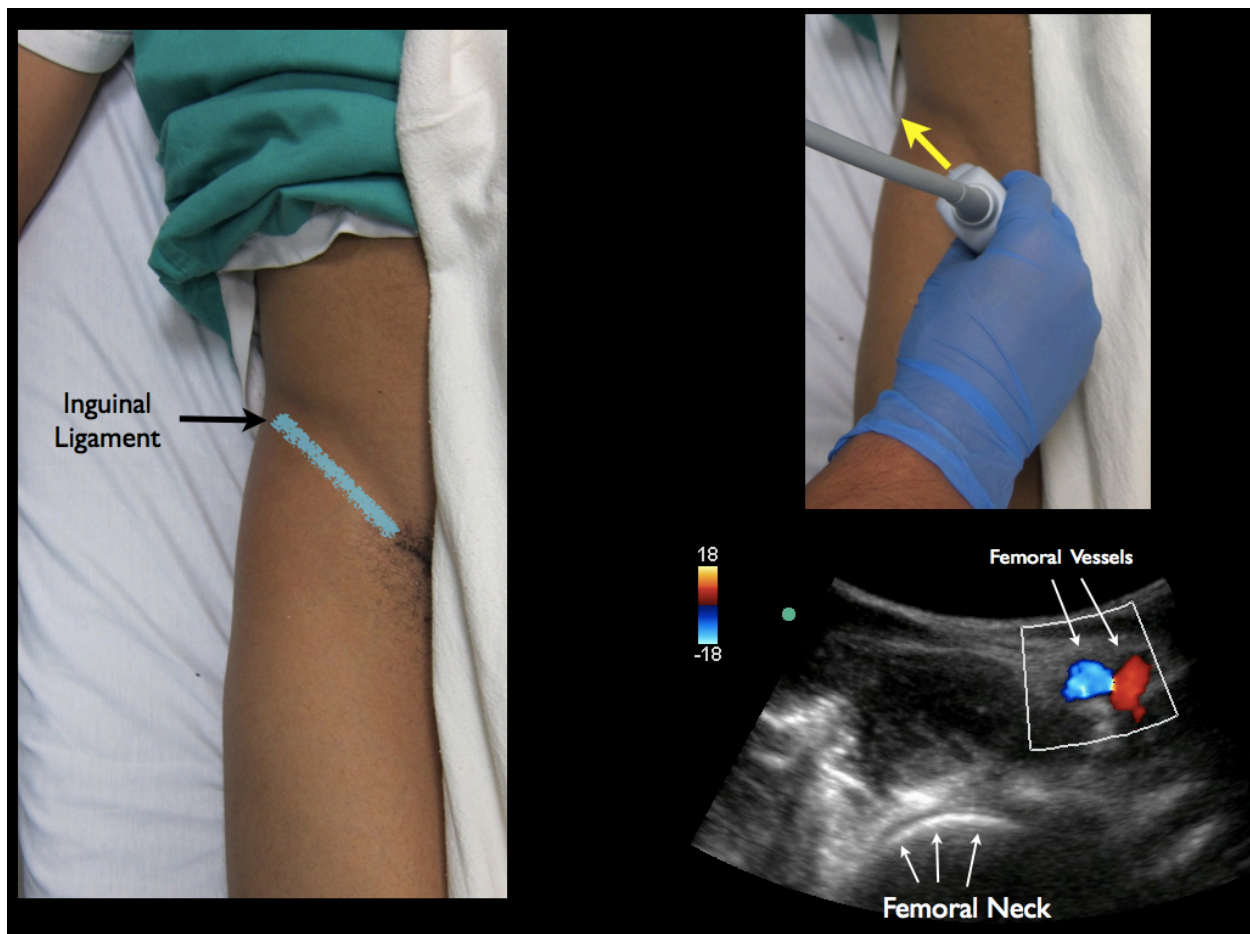
## Step 1

Curvilinear Probe

Probe marker to the patient's right side

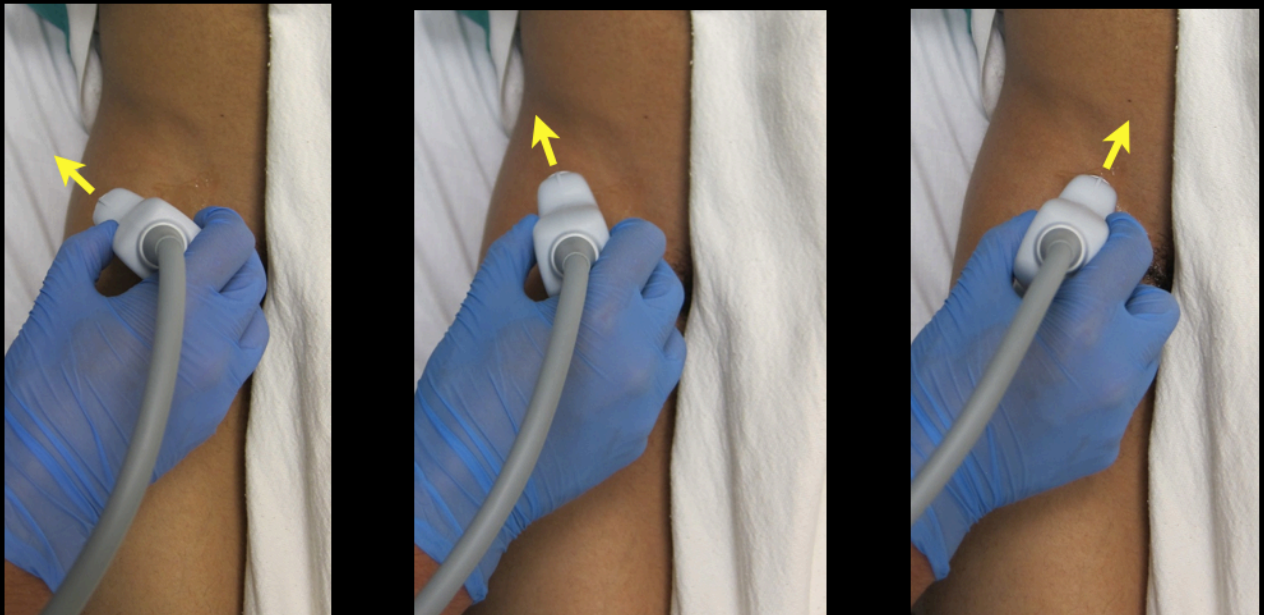
Locate femoral vessels in the near field

Locate the femoral head/neck in the far field



## Step 2

Rotate the Probe marker toward the umbilicus



**Clockwise rotation with the probe marker facing the umbilicus**

### Step 3

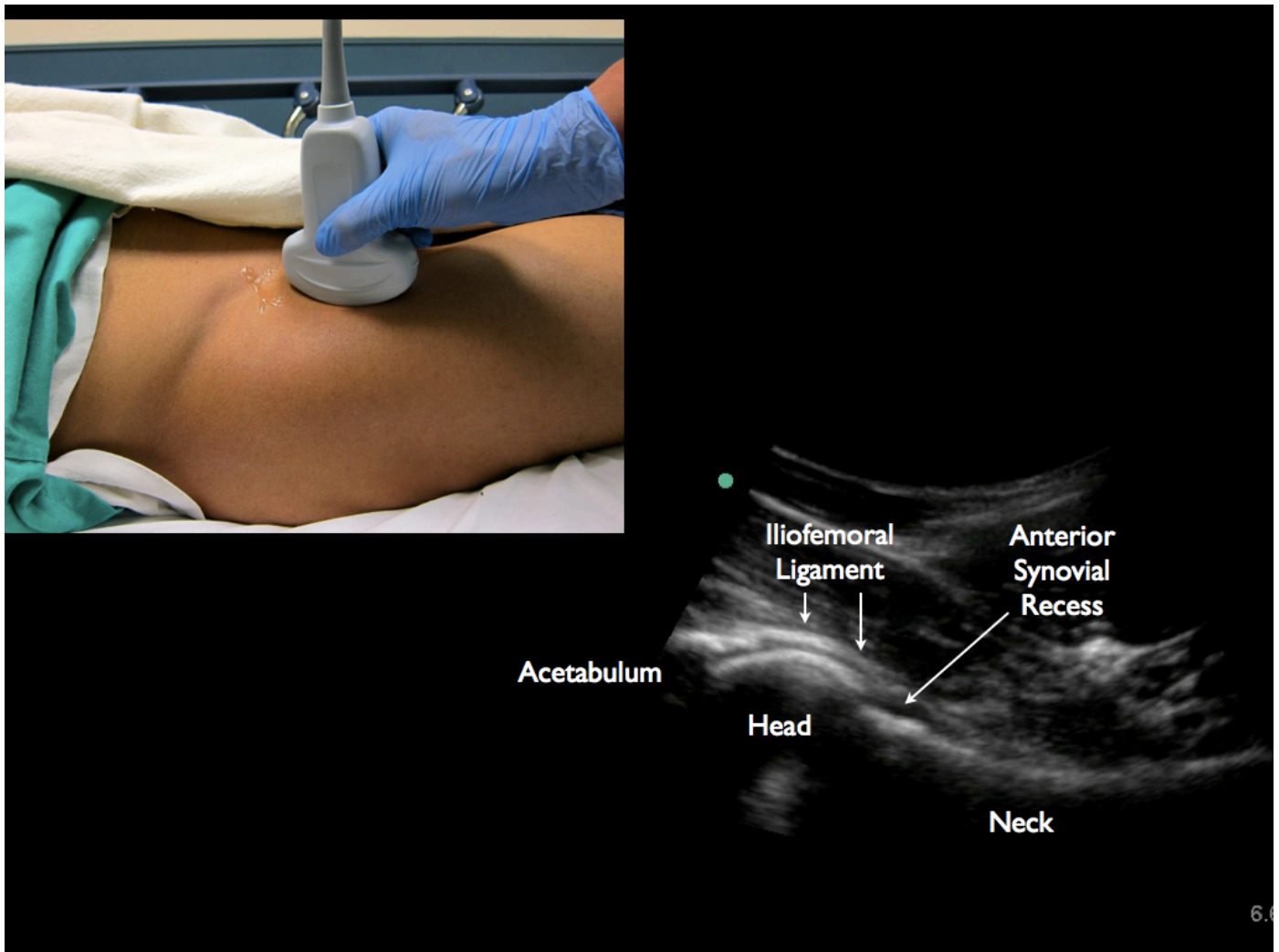
Identify the pertinent Bony Landmarks:

Femoral Head

Femoral Neck

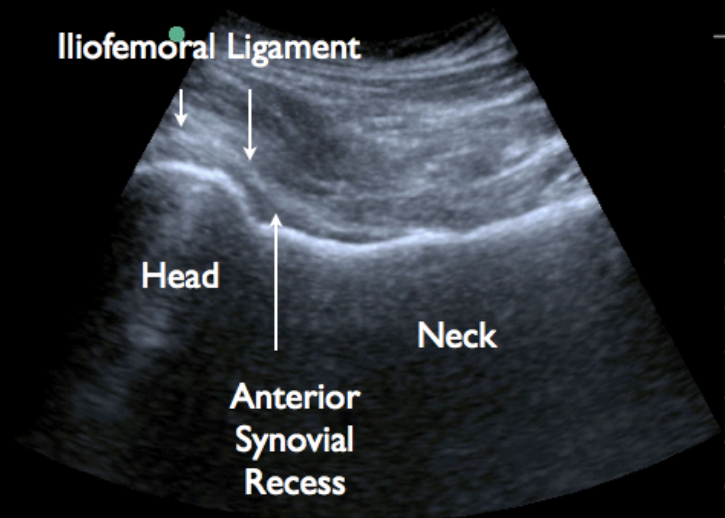
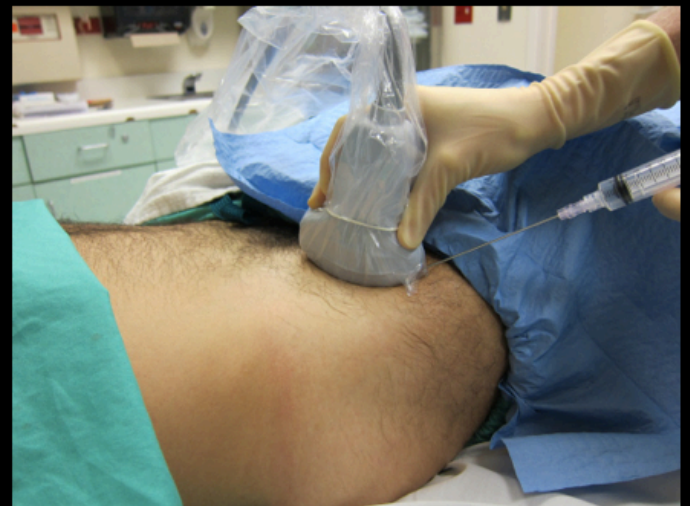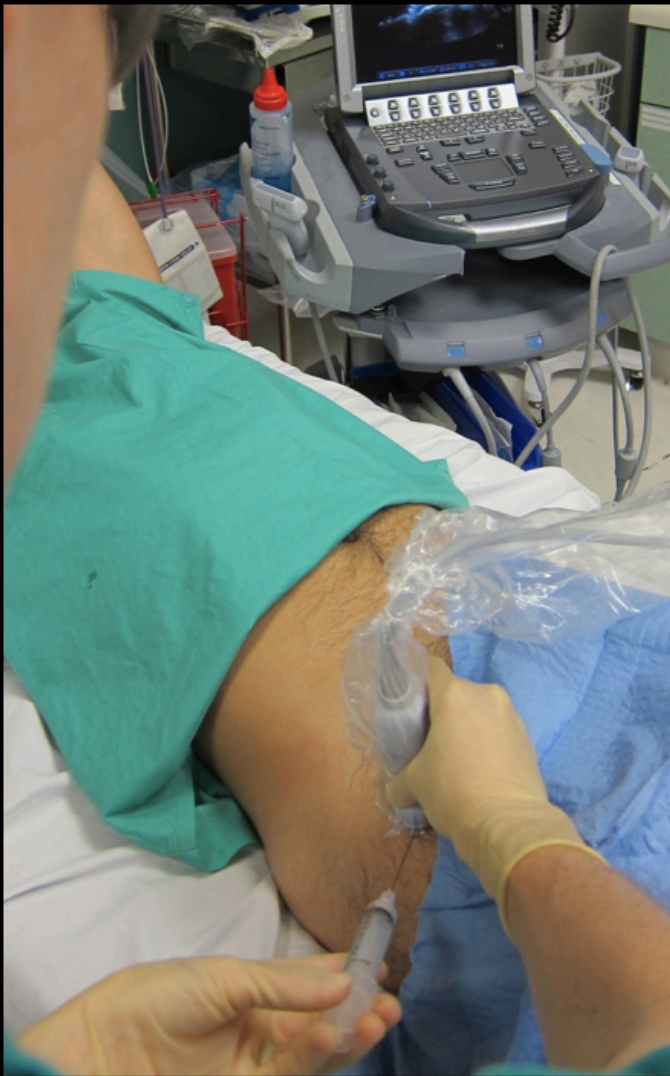Anterior Synovial Recess

Ileofemoral Ligament



## Step 4

Ultrasound Screen in Clear View (contralateral to affected hip)  
Local Anesthetic  
Clean and sterilize the area for needle puncture





## Step 5

20g Spinal Needle attached to a 10cc Syringe  
45 to 60 angle - aimed at the Anterior Synovial Recess  
In-plane needle visualization  
Aspirate as you touch the bony cortex

